

Management of invasive fungal infections: a role for polyenes

Pranatharthi Chandrasekar*

Wayne State University School of Medicine, Detroit, MI, USA

*Harper University Hospital, 390 John R, 5 Hudson, Detroit, MI 48201, USA. Tel: +1-313-745-9649; Fax: +1-313-993-0302;
E-mail: pchandrasekar@med.wayne.edu

The spectrum of invasive fungal infections (IFIs) continues to evolve with the emergence of rare and resistant fungal pathogens. Clinicians are faced with difficult diagnostic and treatment challenges in the management of immunocompromised patients at high risk of developing IFIs. Early and appropriate antifungal therapy is essential for a successful outcome when treating invasive mycoses. The armamentarium of antifungal drugs continues to grow; the three main classes of commonly administered drugs are the polyenes, azoles and echinocandins. The newer triazoles and the echinocandins have changed primary treatment options for some fungal infections, such as aspergillosis and candidiasis. However, despite their toxic potential, the oldest antifungal drugs, polyenes, remain useful in the treatment of IFIs because of their broad-spectrum activity, low rates of resistance and established clinical record, particularly in immunocompromised patients with breakthrough fungal infections. This review highlights important issues in the treatment of IFIs for consideration by clinicians.

Keywords: IFIs, immunocompromised hosts, antifungal therapy

Introduction

Invasive fungal infections (IFIs) are a major cause of morbidity and mortality in immunocompromised patients.¹ The increasing incidence and changing epidemiology of IFIs pose a significant diagnostic and therapeutic challenge in this patient population.^{2,3} Although *Candida albicans*, *Cryptococcus neoformans* and *Aspergillus fumigatus* continue to be the most common causes of opportunistic IFIs,⁴ there are increasing reports of infections with rare/emerging pathogens, including non-*albicans* *Candida* species, opportunistic yeast-like fungi (e.g. *Trichosporon* and *Rhodotorula* spp.), non-*fumigatus* *Aspergillus* spp., Zygomycetes and hyaline moulds (e.g. *Fusarium* and *Scedosporium* spp.).^{4–6} Diagnosing these rare and emerging IFIs is more difficult than diagnosing common IFIs,⁵ and many of these fungi are considered to be more resistant to standard antifungal drugs.^{4,7}

Three main classes of antifungal drugs are available for treating IFIs: polyenes; azoles; and echinocandins. The most commonly used drugs target components of either the fungal cell wall or membrane. With the changing spectrum of pathogens and growing concern over resistance to newer antifungal agents (e.g. azoles and echinocandins),^{8–10} a reassessment of the utility of older, broad-spectrum antifungal agents (e.g. polyenes) may be warranted. This review will provide a brief overview of the spectrum of available antifungal agents, highlight key issues associated with drugs used in the management of fungal infections and summarize current treatment guidelines/options. In addition, two case studies are presented to demonstrate the use of polyenes in patients with breakthrough infections.

Search strategy and selection criteria

Relevant articles were identified by searches of PubMed (1966–2010) using the following search terms: invasive fungal infections; immunocompromised hosts; polyenes; antifungal therapy; resistance; breakthrough fungal infections; azoles; and echinocandins. Search terms were entered either individually or in various combinations. Additional articles were identified by cross-referencing citations from articles identified through PubMed. Only English language reports were reviewed in detail and articles covering relevant topics were included in this manuscript.

Antifungal drugs

Polyenes, azoles and echinocandins have distinct mechanisms of action, and target different sites of the fungal cell wall or membrane (Figure 1).^{1,2,11–14} In addition to the three main drug classes, a number of other agents are being added to the antifungal armamentarium, including allylamines, flucytosine, griseofulvin, sordarins, nikkomycins, ciclopiroxolamine, 1,3-dithian-2-ylidenes and other pyrrole derivatives.² Flucytosine, which is prescribed in combination with amphotericin B, will be discussed briefly.

Polyenes

Introduced in the 1950s, the polyenes represent the oldest family of antifungal drugs.^{1,2} Many polyenes have been isolated

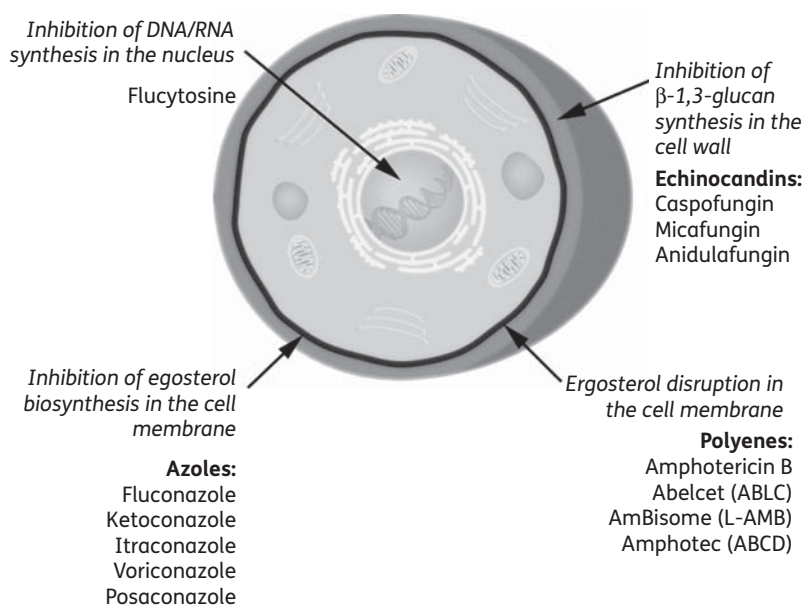


Figure 1. Targets of antifungal drugs in the fungal cell wall, membrane and nucleus. ABCD, amphotericin B colloidal dispersion.

from *Streptomyces* spp.; however, only amphotericin B, lipid formulations of amphotericin B [amphotericin B lipid complex (ABLC), liposomal amphotericin B (L-AMB) and amphotericin B colloidal dispersion] and topical nystatin remain in widespread clinical use.^{2,14–16} The biological activity of amphotericin B is mediated through its binding to ergosterol, an essential component of the fungal cytoplasmic membrane.² Binding results in the formation of aqueous and non-aqueous channels that increase membrane permeability. Cellular components, including proteins and monovalent and divalent cations, flow through these pores, which leads to the loss of membrane potential and, ultimately, cell death.^{1–2,12}

Azoles

Itraconazole, fluconazole and the newer triazoles, voriconazole and posaconazole, are the most commonly used azoles in clinical practice.² The antifungal activity of azoles, like polyenes, is mediated by targeting the fungal cell membrane. Unlike the polyenes, however, azoles interrupt the ergosterol biosynthetic pathway by targeting the cytochrome P (CYP) 450 enzymatic pathway.^{1,17} Ergosterol depletion leads to the accumulation of toxic sterols on the fungal surface, which causes fungal cellular disruption, and inhibits fungal growth and replication.¹

Echinocandins

The echinocandins represent the newest class of antifungal agents developed, and include caspofungin, micafungin and anidulafungin.^{1,18,19} Echinocandins interfere with fungal cell wall synthesis through the non-competitive inhibition of β -1,3-glucan synthesis. β -1,3-Glucan is an integral component of the fungal cell wall.^{19,20} Inhibition of β -1,3-glucan synthesis results in weakening of the cell wall, a breakdown of cellular integrity and, ultimately, cell lysis.¹ The lack of a cell wall in mammalian cells makes this an attractive and specific target for antifungal activity.⁵

5-Flucytosine

Flucytosine is unique in its mechanism of action among antifungal agents; it is the only available antimetabolite.² Some fungal pathogens possess enzymes required to internalize and convert flucytosine to 5-fluorouracil. The incorporation of 5-fluorouracil into a growing RNA molecule causes premature chain termination. In addition, 5-fluorouracil can act on thymidylate synthase to inhibit DNA synthesis. The inhibition of DNA and RNA synthesis subsequently leads to cell death.² Many filamentous fungi lack enzymes necessary for the internalization and conversion of flucytosine; therefore, the fungicidal activity of 5-flucytosine is limited to yeasts, namely *Candida* species and *C. neoformans*.^{2,21}

Spectrum of activity against fungal pathogens

Antifungal agents differ in their spectrum of activity against fungal species (Figure 2).^{2,22–24} Polyenes exhibit the broadest range of activity. They are active against most *Candida* species and *C. neoformans* as well as many moulds, including *Aspergillus* spp., *Fusarium* spp. and Zygomycetes.¹¹ Polyenes are also active against endemic mycoses, but have limited activity against *Scedosporium* spp.^{11,14,25} In addition to their broad spectrum of antifungal activity, a general advantage of polyene therapy is their long history of usage with a low incidence of resistance.³

Azoles vary in their level and complement of activity against fungal species. In general, azoles are effective against *Candida*, *Cryptococcus* and *Aspergillus* spp.^{1,26,27} However, activity against Zygomycetes, *Fusarium* and *Scedosporium* spp. has been mixed.¹¹ Recent data suggest that voriconazole has variable activity against *Fusarium* spp. and may be effective against *Scedosporium* spp.^{28,29} In contrast, posaconazole is effective against Zygomycetes and may be particularly useful as step-down therapy after initial treatment with amphotericin B.^{30–32} Azoles have fungistatic activity against *Candida* and fungicidal activity against *Aspergillus*.

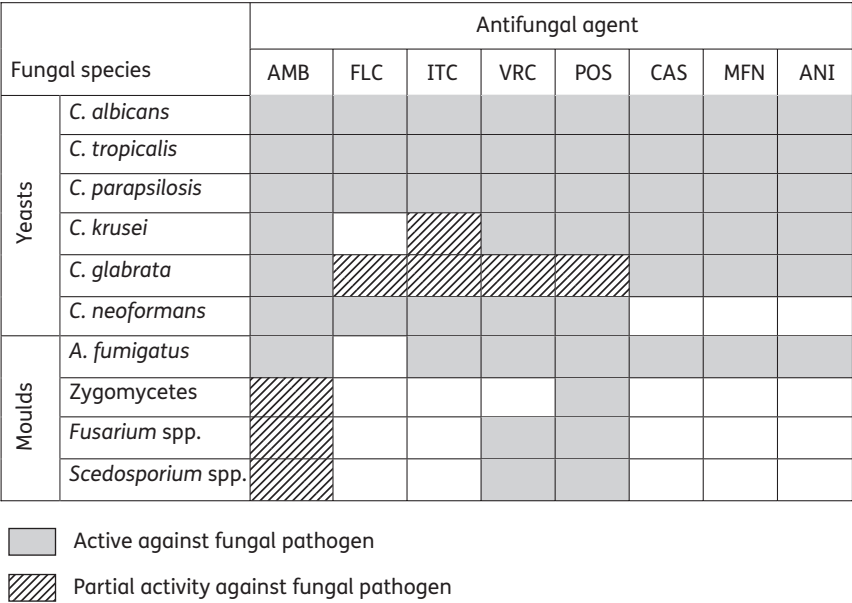


Figure 2. Range of activity of antifungal drugs.^{2,22–24} AMB, amphotericin B (including lipid formulations of amphotericin B); FLC, fluconazole; ITC, itraconazole; VRC, voriconazole; POS, posaconazole; CAS, caspofungin; MFN, micafungin; ANI, anidulafungin.

Echinocandins have a broad spectrum of fungicidal activity against most *Candida* and fungicidal action against the actively growing tips of *Aspergillus* spp.^{18,33} Caspofungin is the only echinocandin approved for the treatment of refractory aspergillosis.³⁴ Echinocandins are not generally active against other fungi that cause invasive mycoses, such as *Cryptococcus* spp., *Fusarium* spp., *Scedosporium* spp. or Zygomycetes, and are not recommended as treatment options for these fungal pathogens.¹⁸

Flucytosine is primarily active against *Candida* spp., *C. neoformans* and certain mould species.³⁵ Reported primary resistance to flucytosine monotherapy among *Candida* and *Cryptococcus* isolates remains very low (<2%).^{35,36} However, the development of secondary resistance has prompted the use of flucytosine in combination with amphotericin B or fluconazole.^{35–37}

Current treatment recommendations/options

An early diagnosis and prompt initiation of appropriate antifungal therapy is important for optimal outcome.^{7,38–41} Effective treatment may involve the surgical debridement of infected tissue and, importantly, immune restoration. Empirical antifungal treatment is often initiated when a microbiological diagnosis of fungal pathogens is unavailable in high-risk patients presenting with clinical signs and symptoms.⁴² Where indicated, polyenes have a valuable role in empirical therapy because of their broad spectrum of fungicidal activity against yeasts and moulds, and a low incidence of resistance.^{3,25} Lipid formulations of amphotericin B have lower toxicity than conventional amphotericin B and represent an effective alternative for certain patients.¹⁴ Table 1 lists potential situations in which the clinical utility of polyenes remains high.^{3,43–45}

Despite their broad range of activity against *Candida* spp., the role of polyene therapy has markedly diminished with the availability of newer azoles and echinocandins.^{3,46} In the recently

Table 1. Clinical utility of polyenes^{3,43–45}

Clinical indication	Polyene therapy
Cryptococcosis	in cases of meningitis or dissemination
Mucormycosis	high dose (≥5 mg/kg/day of lipid-form amphotericin B)
Invasive aspergillosis: voriconazole intolerance or failure	polyene alone or in combination with echinocandins
Suspected invasive mould (mucormycosis ± aspergillosis) infection	empirical therapy
Fusariosis	for species not susceptible to voriconazole
Histoplasmosis, blastomycosis, coccidioidomycosis, sporotrichosis, penicilliosis	in cases of severe infection

published Infectious Diseases Society of America (IDSA) guidelines for the management of candidiasis in non-neutropenic patients, fluconazole or an echinocandin is the preferred option for first-line therapy.⁴⁷ In the neutropenic patient, initial therapy with echinocandins is suggested until the *Candida* sp. is identified. For infections caused by *Candida glabrata*, the IDSA recommends echinocandin therapy, while fluconazole therapy is advised for infections caused by *C. albicans*, *Candida tropicalis* and *Candida parapsilosis*. Polyenes are recommended as alternative therapy in cases of intolerance or limited availability of other antifungal agents. The recommended duration of therapy for candidiasis is 2 weeks following documented clearance and symptom resolution.⁴⁷

Polyenes remain a part of the recommended initial frontline treatment regimen for patients with cryptococcosis. The National Institute of Allergy and Infectious Diseases Mycoses Study Group established specific guidelines that are dependent upon the anatomical site of involvement (e.g. CNS versus non-CNS involvement) and the patient's immune status (e.g. with or without HIV infection).⁴⁸ For HIV-negative patients with CNS involvement, combined treatment with amphotericin B and flucytosine for 2 weeks, followed by 8–10 weeks of consolidation with fluconazole, is recommended.⁴⁸ Consolidation therapy with fluconazole may be extended for up to 12 months if necessary, depending on the patient's clinical status. The recently published guidelines for the management of cryptococcal disease recommend ≥ 4 weeks of induction therapy with amphotericin B plus flucytosine in non-HIV-infected, non-transplant hosts with CNS involvement. The new guidelines also advise substitution with ABLC or L-AMB if patients are intolerant of conventional amphotericin B.⁴⁹ In HIV-negative patients with pulmonary disease, azole monotherapy with fluconazole is recommended as first-line treatment; itraconazole or amphotericin B are acceptable alternatives. All formulations of amphotericin B are recommended for severe pulmonary cryptococcal disease. The preferred treatment for patients with HIV and cryptococcal meningitis is amphotericin B and flucytosine for 2–10 weeks, followed by fluconazole maintenance therapy. The use of lipid formulations of amphotericin B is dictated by the patient's underlying renal function; lipid formulations of amphotericin B may be substituted in patients with, or those predisposed to, renal dysfunction.⁴⁹ In a direct head-to-head comparison of L-AMB or amphotericin B as induction therapy for acute cryptococcal meningitis in HIV-positive patients, the efficacy of the liposomal formulation was not superior to that of amphotericin B, but the former had significantly less toxicity.⁵⁰

Voriconazole has replaced amphotericin B as the recommended therapy for treatment of invasive aspergillosis.^{51–53} Reasonable management options for refractory aspergillosis include dosage adjustments, a change in drug class or combination antifungal therapy.⁵¹ Lipid formulations of amphotericin B may be used as alternatives in patients who are intolerant of voriconazole or who have refractory aspergillosis.⁵⁴ Recently published IDSA guidelines acknowledge the fact that significant knowledge gaps remain with respect to the best treatment regimen for refractory aspergillosis.⁵¹ Managing breakthrough IFIs remains difficult and depends upon good clinical judgement.⁵⁵

There are no established guidelines for the treatment of rare and emerging mould infections.¹ Zygomycetes infections are resistant to echinocandins and azoles, including voriconazole. The incidence of breakthrough infections caused by Zygomycetes in patients receiving therapy for invasive aspergillosis is on the rise.^{7,56} Amphotericin B formulations and posaconazole have demonstrated activity against mucormycosis.^{7,14,57–59} Lipid forms of amphotericin B are utilized as first-line therapy for mucormycosis, often supplemented by surgical debridement,^{7,14,60} and polyene therapy is often switched to oral posaconazole after clinical stabilization.⁵⁹ The duration of therapy remains unclear and is usually based upon clinical and radiological status, and correction of the underlying immune deficit.⁵⁹

Conventional amphotericin B is the drug of choice for induction therapy of moderate to severe cases of histoplasmosis,

while itraconazole and fluconazole are effective for induction and consolidation therapy in milder cases of histoplasmosis.⁶¹ In a study conducted in patients with AIDS, L-AMB demonstrated lower toxicity, superior efficacy and improved survival, suggesting that it may be an attractive alternative to conventional amphotericin B in the treatment of moderate to severe disseminated histoplasmosis.⁶¹

Fusariosis is an uncommon fungal infection usually diagnosed in immunocompromised patients with prolonged neutropenia or after corticosteroid use for graft-versus-host disease (GVHD) in stem cell transplant patients.^{11,62,63} Some *Fusarium* spp. are susceptible to polyene therapy, but resistant to voriconazole, while others may only be susceptible to voriconazole.^{3,62} In the Collaborative Exchange of Antifungal Research database, ABLC was administered as first-line or second-line therapy;⁶⁴ 46% of evaluable patients with fusariosis ($n=26$) were cured or improved and 12% were stabilized.⁶⁵

First-line therapy for scedosporiosis has not yet been firmly established. *Scedosporium apiospermum* infections may generally be treated with voriconazole; polyenes are ineffective against this fungal species. *In vitro* studies suggest that there may be synergistic interaction between polyenes and echinocandins (micafungin) against *Scedosporium* spp.⁶⁶ Evidence also suggests that combination therapy with voriconazole and terbinafine may be effective against *Scedosporium prolificans* infections.⁶⁷

Issues with azole and echinocandin therapy

Resistance to antifungal drugs has become an important clinical problem with azoles.^{9,10} Molecular mechanisms for resistance are poorly understood.^{8,35} Recognized mechanisms for azole resistance include reduced intracellular accumulation of drugs (due to either decreased uptake or increased efflux), altered ergosterol biosynthetic enzymes, amplification of genes encoding target enzymes and development of pathways bypassing target enzymes.^{35,68} Resistance to azoles in *A. fumigatus* is being recognized as a potential clinical problem.^{69,70} Resistance becomes relevant in the clinical setting as a result of the replacement of an initially susceptible species by intrinsically resistant pathogens or selection of a more resistant strain of the same species.³⁵

Azoles may serve as inhibitors of or substrates for several CYP 450 isoenzymes to a varied extent, which may contribute to significant drug interactions (Tables 2 and 3).^{19,52} In addition, serum levels of azoles (voriconazole, in particular) may need to be monitored to avoid toxicities and ensure efficacy.^{52,59,71,72} The need for monitoring is underscored by the unpredictable relationship between dosing and plasma concentrations for several of the azoles.^{73–75} While the need for serum concentration monitoring is gaining clinical attention (particularly voriconazole and posaconazole), few laboratories currently perform these drug assays on a routine basis.⁵²

One drawback of an echinocandin is its limited spectrum of activity. It has fungicidal effects on *Candida* spp., but static activity against *Aspergillus*. Although resistance to *Candida* spp. is rare, a few case reports suggest that resistance to echinocandins may be seen in *Candida* spp., including *C. albicans*, *C. glabrata*, *Candida krusei* and *C. parapsilosis*.^{76–79}

Table 2. Interactions of azoles with the cytochrome system^{19,22}

Azole	Cytochrome P450 interactions	
Fluconazole	inhibitor	2C19+, 2C9++, 3A4+++
Itraconazole	inhibitor	2C9+, 3A4+++
	substrate	3A4+++
Voriconazole	inhibitor	2C19+++ , 2C9++, 3A4++
	substrate	2C19+++ , 2C9+, 3A4+
Posaconazole	inhibitor	3A4+++

Degree of activity: +, minimal effect; ++, moderate effect; and +++, strong effect.

Table 3. Major drug–drug interaction with azoles^{19,52}

Azole	Increase concentration of non-antifungal drug	Decrease concentration of antifungal drug
Fluconazole	phenytoin, warfarin, rifamycins	phenytoin
Itraconazole	calcineurin inhibitors, sirolimus, statins, phenytoin, warfarin, rifamycins	phenytoin, carbamazepine
Voriconazole	calcineurin inhibitors, sirolimus ^a , statins, phenytoin, warfarin, rifamycins ^a	phenytoin, carbamazepine ^a , efavirenz ^a
Posaconazole	calcineurin inhibitors, sirolimus, phenytoin, warfarin, rifamycins	phenytoin, rifabutin

^aContraindicated.

Against *C. parapsilosis*, echinocandins have intrinsically low activity *in vitro*. Echinocandins are safe, with fewer drug interactions compared with polyenes and azoles.⁵² In contrast to azoles, drug–drug interactions are not a concern for the echinocandins.⁸⁰

Issues related to treatment with polyenes

The most significant side effect associated with conventional amphotericin B usage is renal toxicity.^{1,81} Lipid formulations of amphotericin B are less nephrotoxic than conventional amphotericin and may be administered safely.^{1,3,82} While acute liver failure is rarely reported in patients receiving polyene therapy, hepatotoxicity is a concern; an increased incidence of hepatocellular and cholestatic injury, as well as increased alanine transaminase and aspartate transaminase levels are associated with polyene treatment.⁸³ Infusion-related reactions, which include fever, chills and shaking, are a serious concern with polyene therapy.¹ These reactions have been reported both with conventional and lipid formulations of amphotericin B,^{82,25} although the incidence is significantly reduced with the latter. L-AMB is associated with fewer infusion-related reactions than ABLC. Whether the two lipid forms of amphotericin B have varying nephrotoxicity potential remains unclear.^{81,84–89}

Polyenes have a broad spectrum of activity, with few reports of resistance. However, limited activity against *Aspergillus terreus*, *Aspergillus ustus* and *Scedosporium* spp. has to be taken into consideration with polyene therapy.²⁵

Case studies of infection breakthrough: value of polyenes

Prolonged use of antifungal agents may increase the risk of emergence of ‘resistant’ organisms in immunocompromised hosts. For example, Zygomycetes and *A. ustus* infections have emerged in stem cell transplant recipients receiving voriconazole.^{90,91} Breakthrough invasive aspergillosis has also been reported in haematopoietic stem cell transplant recipients receiving caspofungin.⁹² The following case studies illustrate instances in which patients receiving azole prophylaxis/therapy developed breakthrough infections that responded to polyene therapy.

Case study I

A patient with diabetes mellitus and acute myelogenous leukaemia underwent HLA-matched, sibling-donor peripheral blood stem cell transplantation. A significant complication included acute GVHD of the skin and liver, which responded to therapy with methylprednisolone along with tacrolimus.

Two years later, a flare up of GVHD of the skin occurred and lung GVHD (bronchiolitis obliterans) was diagnosed. The dose of tacrolimus was increased and corticosteroid therapy (40 mg methylprednisolone twice daily) was reinstituted. Antifungal prophylaxis with oral posaconazole (200 mg three times daily) was initiated. Six weeks later, with a tapering dose of methylprednisolone, the patient presented with complaints of dry cough, shortness of breath, left-sided pleuritic chest pain, low-grade fever and fatigue of 1 week duration. On examination, the patient was alert, febrile and oriented, and in mild respiratory distress. Air entry was markedly diminished over the mid and lower zones of the left lung; no pleural rub or rales was detected. Laboratory values were: haemoglobin, 11.2 g/dL; white blood cell count, 8000/mm³; platelet count, 169 000/mm³; serum creatinine, 1 mg/dL; and serum glucose, 111%. Liver function tests were normal; the serum aspergillus galactomannan level was 0.08 (normal <0.5). Chest X-ray showed two well-rounded, thick-walled cavities with air fluid levels in the left mid and lower lung fields (Figure 3a). A chest CT scan revealed a round cavity-like lesion with fluid and an air pocket in the left lower lung (Figure 3b). A CT-guided transthoracic lung biopsy was negative on culture for bacteria, viruses and fungi; the histopathology revealed acute and chronic inflammatory changes, and fungal hyphal elements suspicious for *Mucor*.

Prophylaxis with posaconazole was discontinued and antifungal therapy was initiated with ABLC, administered intravenously at 7.5 mg/kg/day for pulmonary mucormycosis. The patient continued to have dry cough, mild shortness of breath and low-grade fever despite 10 days of treatment with ABLC. The patient then underwent a left lower lung lobectomy, decortication and mediastinal node dissection. Pathology of the removed lung showed two large areas of necrotizing granuloma with surrounding pneumonitis; fungal hyphae consistent with

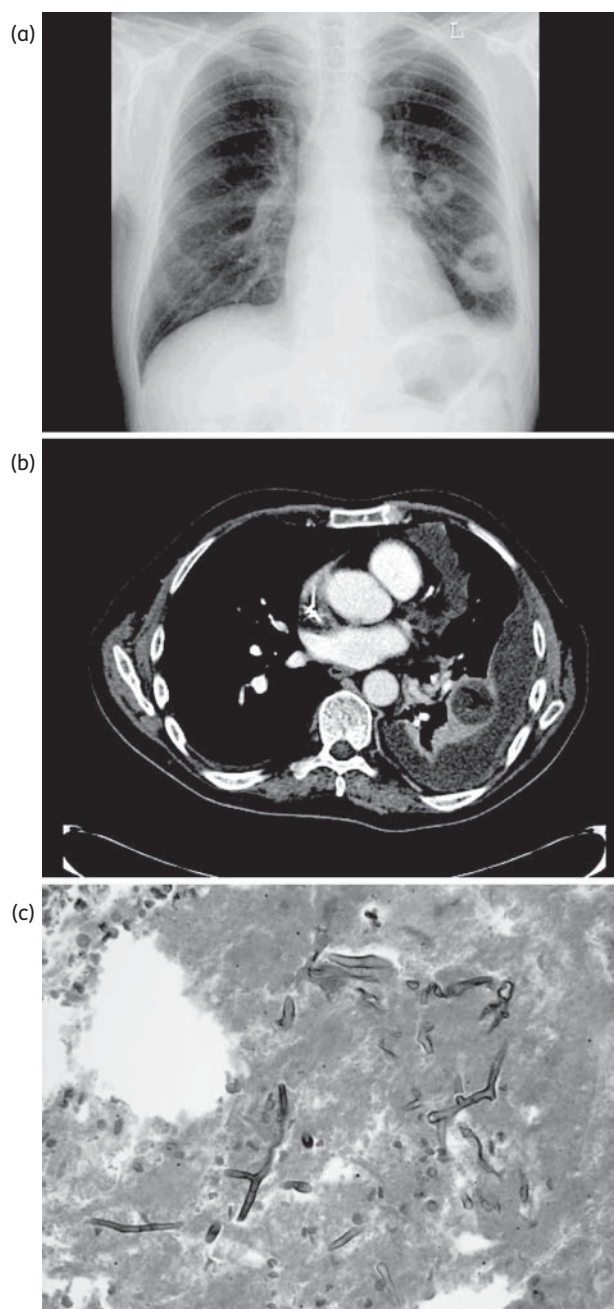


Figure 3. A chest X-ray taken 3 days before the initiation of treatment with ABLC showed two well-rounded, thick-walled cavities with air fluid levels in the left mid and lower lung fields (a). A chest CT scan revealed a round cavity-like lesion with fluid and an air pocket in the left lower lung (b). A left lower lung lobectomy was performed and two large areas of necrotizing granulomas with fungal hyphae consistent with *Mucor* were identified (c).

Mucor were seen within the granuloma (Figure 3c). Serum creatinine levels gradually rose to 1.6 mg/dL and, so, after 2 weeks of 7.5 mg/kg/day ABLC, the dose was decreased to 5 mg/kg/day. Clinical improvement was noted. After 2 months of therapy with ABLC, treatment was changed to 400 mg oral posaconazole twice daily. At 1 year follow-up, the patient was doing well.

In this patient, breakthrough pulmonary mucormycosis occurred, despite prophylaxis with posaconazole. After surgical resection and several weeks of intravenous ABLC, step-down therapy with oral posaconazole was instituted with successful outcome.

Case study II

A patient with a history of myelodysplastic syndrome underwent an HLA-matched, sibling-donor allogeneic hematopoietic stem cell transplantation. The conditioning regimen consisted of busulfan and fludarabine; thymoglobulin was administered as prophylaxis against GVHD. Both the donor and recipient were seronegative for cytomegalovirus. The patient developed GVHD of the gastrointestinal tract, for which therapy with tacrolimus and methylprednisolone was administered. Concomitantly, prophylaxis with 200 mg oral voriconazole twice daily was initiated. A random level of voriconazole obtained ~1 month later was 0.8 mg/L.

Four months later, the patient was admitted with fever, cough and shortness of breath. Physical examination showed a temperature of 101°F, a pulse of 100/min, respiration of 18 breaths/min, blood pressure of 100/80 mm Hg and oxygen saturation of 96% on 2 L of oxygen. Chest X-ray and CT scan revealed a consolidated mass in the left upper lobe of the lung. Bronchoalveolar lavage (BAL) did not yield any positive results. Serum aspergillus galactomannan and BAL fluid galactomannan were negative; however, serum β -D-glucan was >500 pg/mL. A wedge biopsy of the left lung was performed; acute and chronic inflammatory changes were noted on histopathological examination of the lung, but no aetiological diagnosis was established. Specific stains and cultures of the lung specimen for bacteria, viruses and fungi were negative. Based on the clinical presentation, serum β -D-glucan level and biopsy findings, breakthrough invasive filamentous fungal infection was suspected. Prophylaxis with voriconazole was stopped and therapy with ABLC (5 mg/kg/day) was initiated. The patient tolerated the treatment with ABLC well, with good clinical and radiological improvement. After 3 weeks of antifungal therapy, the serum β -D-glucan test was negative. No renal toxicity was observed during the 2 month period of treatment with ABLC. At the 3 month follow-up after discontinuation of antifungal therapy, the patient appeared to be doing well clinically, with good radiological improvement of the left lung lesion.

This patient had probable breakthrough IFI, despite prophylaxis with voriconazole. Failure of histopathological examination and culture of tissue to reveal a fungal pathogen in the setting of an IFI is not rare. Successful therapy was achieved with intravenous ABLC.

Discussion and conclusions

The spectrum of IFIs among immunosuppressed patients continues to evolve with the increasing incidence of rare and emerging pathogens, and poses a significant challenge in the diagnosis and treatment of these patients. Early and appropriate antifungal therapy is important for successful outcomes. Polyenes are the oldest antifungal drugs, and lipid formulations of amphotericin B have reduced nephrotoxicity and less infusion-related reactions associated with conventional amphotericin B.

Azoles, especially newer triazoles, have activity against a broad spectrum of fungal pathogens and have replaced polyenes as initial therapy for aspergillosis. However, toxicities and drug interactions are common occurrences with newer triazoles, and clinicians should carefully monitor patients for therapeutic drug levels and toxicities. *Candida* resistance to azoles is of concern and *Aspergillus* resistance has been reported. Echinocandins have a good safety profile and are highly active against *Candida* infections; they are now recommended as the primary treatment option for candidiasis. However, they do not have activity against *Cryptococcus*, *Fusarium* and *Scedosporium* spp. or Zygomycetes.

Despite their potential toxicity, polyenes remain useful in the treatment of IFIs because of their long track record, broad spectrum of activity and low rates of documented resistance. With prolonged use of antifungal drugs, particularly azoles and echinocandins, in prophylactic and empirical settings in immunocompromised individuals, clinicians should anticipate breakthrough infections.^{5,91,93} Whenever possible, accurate identification of the infecting organism is critical for the optimal management of breakthrough IFIs.

Transparency declarations

None to declare.

References

- Mohr J, Johnson M, Cooper T et al. Current options in antifungal pharmacotherapy. *Pharmacotherapy* 2008; **28**: 614–45.
- Mathew BP, Nath M. Recent approaches to antifungal therapy for invasive mycoses. *ChemMedChem* 2009; **4**: 310–23.
- Chandrasekar PH. Amphotericin B lipid complex: treatment of invasive fungal infections in patients refractory to or intolerant of amphotericin B deoxycholate. *Ther Clin Risk Manag* 2008; **4**: 1285–94.
- Pfaller MA, Pappas PG, Wingard JR. Invasive fungal pathogens: current epidemiological trends. *Clin Infect Dis* 2006; **43**: S3–14.
- Lai CC, Tan CK, Huang YT et al. Current challenges in the management of invasive fungal infections. *J Infect Chemother* 2008; **14**: 77–85.
- Chandrasekar P. Invasive mold infections: recent advances in management approaches. *Leuk Lymphoma* 2009; **50**: 703–15.
- Chamilos G, Lewis RE, Kontoyiannis DP. Delaying amphotericin B-based frontline therapy significantly increases mortality among patients with hematologic malignancy who have zygomycosis. *Clin Infect Dis* 2008; **47**: 503–9.
- Perlin DS. Resistance to echinocandin-class antifungal drugs. *Drug Resist Updat* 2007; **10**: 121–30.
- Snelders E, van der Lee HAL, Kuijpers J et al. Emergence of azole resistance in *Aspergillus fumigatus* and spread of a single resistance mechanism. *PLoS Med* 2008; **5**: 1629–37.
- Masia Canuto M, Gutierrez Rodero F. Antifungal resistance to azoles and polyenes. *Lancet Infect Dis* 2002; **2**: 550–63.
- Cornely OA. *Aspergillus* to Zygomycetes: causes, risk factors, prevention, and treatment of invasive fungal infections. *Infection* 2008; **36**: 296–313.
- Metcalfe SC, Dockrell DH. Improved outcomes associated with advances in therapy for invasive fungal infections in immunocompromised hosts. *J Infection* 2007; **55**: 287–99.
- Thompson GR III, Cadena J, Patterson TF. Overview of antifungal agents. *Clin Chest Med* 2009; **30**: 203–15.
- Moen MD, Lyseng-Williamson KA, Scott LJ. Liposomal amphotericin B: a review of its use as empirical therapy in febrile neutropenia and in the treatment of invasive fungal infections. *Drugs* 2009; **69**: 361–92.
- Lanternier F, Lortholary O. Liposomal amphotericin B: what is its role in 2008? *Clin Microbiol Infect* 2008; **14** Suppl 4: 71–83.
- Linden PK. Amphotericin B lipid complex for the treatment of invasive fungal infections. *Expert Opin Pharmacother* 2003; **4**: 2099–110.
- Dodds-Ashley ES. Treatment options for invasive fungal infections. *Pharmacotherapy* 2006; **26**: 55S–60S.
- Kauffman CA, Carver PL. Update on echinocandin antifungals. *Semin Respir Crit Care Med* 2008; **29**: 211–9.
- Zaas AK. In the modern day, what are the potential advantages of echinocandins over azoles and polyenes in drug interactions? *J Inv Fungal Infect* 2007; **1**: 133–43.
- Rogers TR, Frost S. Newer antifungal agents for invasive fungal infections in patients with haematological malignancy. *Br J Haematol* 2009; **144**: 629–41.
- Pfaller MA, Messer SA, Boyken L et al. In vitro activities of 5-fluorocytosine against 8,803 clinical isolates of *Candida* spp.: global assessment of primary resistance using National Committee for Clinical Laboratory Standards susceptibility testing methods. *Antimicrob Agents Chemother* 2002; **46**: 3518–21.
- Dodds-Ashley ES, Lewis J et al. Pharmacology of systemic antifungal agents. *Clin Infect Dis* 2006; **43**: S28–39.
- Pfaller MA, Messer SA, Boyken L et al. In vitro activities of voriconazole, posaconazole, and fluconazole against 4,169 clinical isolates of *Candida* spp. and *Cryptococcus neoformans* collected during 2001 and 2002 in the ARTEMIS global antifungal surveillance program. *Diagn Microbiol Infect Dis* 2004; **48**: 201–5.
- Zhanel GG, Karlowsky JA, Harding GA et al. In vitro activity of a new semisynthetic echinocandin, LY-303366, against systemic isolates of *Candida* species, *Cryptococcus neoformans*, *Blastomyces dermatitidis*, and *Aspergillus* species. *Antimicrob Agents Chemother* 1997; **41**: 863–5.
- Cornely OA, Vehreschild JJ, Ullmann AJ. Is there a role for polyenes in treating invasive mycoses? *Curr Opin Infect Dis* 2006; **19**: 565–70.
- Dromer R, Mathoulis S, Dupont B et al. Comparison of the efficacy of amphotericin B and fluconazole in the treatment of cryptococcosis in human immuno-deficiency virus-negative patients: retrospective analysis of 83 cases. French Cryptococcosis Study Group. *Clin Infect Dis* 1996; **22** Suppl 2: S154–60.
- Denning DW, Lee JY, Hostetler JS et al. NIAID mycoses study group multicenter trial of oral itraconazole therapy for invasive aspergillosis. *Am J Med* 1994; **97**: 135–44.
- Espinel-Ingroff A, Johnson E, Hockey H et al. Activities of voriconazole, itraconazole and amphotericin B in vitro against 590 moulds from 323 patients in the voriconazole Phase III clinical studies. *J Antimicrob Chemother* 2008; **61**: 616–20.
- Guinea J, Peláez T, Recio S et al. In vitro antifungal activities of isavuconazole (BAL4815), voriconazole, and fluconazole against 1,007 isolates of zygomycete, *Candida*, *Aspergillus*, *Fusarium*, and *Scedosporium* species. *Antimicrob Agents Chemother* 2008; **52**: 1396–400.
- Dannaoui E, Meletiadis JW, Mouton JW et al. In vitro susceptibilities of zygomycetes to conventional and new antifungals. *J Antimicrob Chemother* 2003; **51**: 45–52.
- Sun QN, Fothergill AW, McCarthy DI et al. In vitro activities of posaconazole, amphotericin B, and fluconazole against 37 clinical

- isolates of zygomycetes. *Antimicrob Agents Chemother* 2002; **46**: 1581–2.
- 32** van Burik JA, Hare RS, Solomon HF *et al*. Posaconazole is effective as salvage therapy in zygomycosis: a retrospective summary of 91 cases. *Clin Infect Dis* 2006; **42**: e61–5.
- 33** Denning DW, Marr KA, Lau WM *et al*. Micafungin (FK463), alone or in combination with other systemic antifungal agents, for the treatment of acute invasive aspergillosis. *J Infect* 2006; **53**: 337–49.
- 34** *Cancidas® Prescribing Information*. Whitehouse Station, NJ: Merck & Co., Inc., July 2008.
- 35** Peman J, Canton E, Espinel-Ingroff A. Antifungal drug resistance mechanisms. *Expert Rev Infect Ther* 2009; **7**: 453–60.
- 36** Hospenthal DR, Bennett JE. Flucytosine monotherapy for cryptococcosis. *Clin Infect Dis* 1998; **27**: 260–4.
- 37** Espinel-Ingroff A. Mechanisms of resistance to antifungal agents: yeasts and filamentous fungi. *Rev Iberoam Micol* 2008; **25**: 101–6.
- 38** Garey KW, Rege M, Pai MP *et al*. Time to initiation of fluconazole therapy impacts mortality in patients with candidemia: a multi-institutional study. *Clin Infect Dis* 2006; **43**: 25–31.
- 39** Greene RE, Schlamm HT, Oestmann JW *et al*. Imaging findings in acute invasive pulmonary aspergillosis: clinical significance of the halo sign. *Clin Infect Dis* 2007; **44**: 373–9.
- 40** von Eiff M, Roos N, Schulten R *et al*. Pulmonary aspergillosis: early diagnosis improves survival. *Respiration* 1995; **62**: 341–7.
- 41** Parkins MD, Sabuda DM, Elsayed S *et al*. Adequacy of empirical antifungal therapy and effect on outcome among patients with invasive *Candida* species infections. *J Antimicrob Chemother* 2007; **60**: 613–8.
- 42** Zaragoza R, Pemán J, Salavert M *et al*. Multidisciplinary approach to the treatment of invasive fungal infections in adult patients. Prophylaxis, empirical, preemptive or targeted therapy, which is the best in the different hosts? *Ther Clin Risk Manag* 2008; **4**: 1261–80.
- 43** Reed C, Bryant R, Ibrahim AS *et al*. Combination polyene–caspofungin treatment of rhino-orbital-cerebral mucormycosis. *Clin Infect Dis* 2008; **47**: 364–71.
- 44** Ellis D. Amphotericin B: spectrum and resistance. *J Antimicrob Chemother* 2002; **49** Suppl 1: 7–10.
- 45** Prasad PA, Coffin SE, Leckerman KH *et al*. Pediatric antifungal utilization. New drugs, new trends. *Pediatr Infect Dis J* 2008; **27**: 1083–8.
- 46** Cao C, Liu W, Li R *et al*. In vitro interactions of micafungin with amphotericin B, itraconazole or fluconazole against the pathogenic phase of *Penicillium marneffeii*. *J Antimicrob Chemother* 2009; **63**: 340–2.
- 47** Pappas PG, Kauffman CA, Andes D *et al*. Clinical practice guidelines for the management of candidiasis: 2009 update by the Infectious Diseases Society of America. *Clin Infect Dis* 2009; **48**: 503–35.
- 48** Saag MS, Graybill RJ, Larsen RA *et al*. Practice guidelines for the management of cryptococcal disease. Infectious Diseases Society of America. *Clin Infect Dis* 2000; **30**: 710–8.
- 49** Perfect JR, Dismukes WE, Dromer F *et al*. Clinical practice guidelines for the management of cryptococcal disease: 2010 update by the Infectious Diseases Society of America. *Clin Infect Dis* 2010; **50**: 291–322.
- 50** Hamill RJ, Sobel J, El-Sadr W *et al*. Comparison of 2 doses of liposomal amphotericin B and conventional amphotericin B deoxycholate for treatment of AIDS-associated acute cryptococcal meningitis: a randomized, double blind clinical trial of efficacy and safety. *Clin Infect Dis* 2010; **51**: 225–32.
- 51** Mosquera J, Denning DW. Azole cross-resistance in *Aspergillus fumigatus*. *Antimicrob Agents Chemother* 2002; **46**: 556–7.
- 52** Wilson DT, Drew RH, Perfect JR. Antifungal therapy for invasive fungal diseases in allogeneic stem cell transplant recipients: an update. *Mycopathologia* 2009; **168**: 313–27.
- 53** Herbrecht R, Denning DW, Patterson TF *et al*. Voriconazole versus amphotericin B for primary therapy of invasive aspergillosis. *N Engl J Med* 2002; **347**: 408–15.
- 54** Krishnan-Natesan S, Chandrasekar PH. Current and future therapeutic options in the management of invasive aspergillosis. *Drugs* 2008; **68**: 265–82.
- 55** Nailor MD, Chandrasekar PH. Treatment of breakthrough fungal infections: is there one best drug strategy? *Curr Fungal Infect Rep* 2009; **3**: 229–35.
- 56** Kontoyiannis DP, Lionakis MS, Lewis RE *et al*. Zygomycosis in a tertiary-care cancer center in the era of *Aspergillus*-active antifungal therapy: a case-control observational study of 27 recent cases. *J Infect Dis* 2005; **191**: 1350–60.
- 57** Rogers TR. Treatment of zygomycosis: current and new options. *J Antimicrob Chemother* 2008; **61** Suppl 1: i35–9.
- 58** Smith WJ, Drew RH, Perfect JR. Posaconazole's impact on prophylaxis and treatment of invasive fungal infections: an update. *Expert Rev Anti Infect Ther* 2009; **7**: 165–81.
- 59** Morris MI. Posaconazole: a new oral antifungal agent with an expanded spectrum of activity. *Am J Health Syst Pharm* 2009; **66**: 225–36.
- 60** Spellberg B, Walsh TJ, Kontoyiannis DP *et al*. Recent advances in the management of mucormycosis: from bench to bedside. *Clin Infect Dis* 2009; **48**: 1743–51.
- 61** Johnson PC, Wheat J, Cloud GA *et al*. Safety and efficacy of liposomal amphotericin B compared with conventional amphotericin B for induction therapy of histoplasmosis in patients with AIDS. *Ann Intern Med* 2002; **137**: E105–10.
- 62** Lionakis MS, Kontoyiannis DP. *Fusarium* infections in critically ill patients. *Semin Respir Crit Care Med* 2004; **25**: 159–69.
- 63** Nucci M, Anaissie EJ, Queiroz-Telles F *et al*. Outcome predictors of 84 patients with hematologic malignancies and *Fusarium* infection. *Cancer* 2003; **98**: 315–9.
- 64** Pappas PG. Amphotericin B lipid complex in the treatment of invasive fungal infections: results of the Collaborative Exchange of Antifungal Research (CLEAR), an industry-supported patient registry. *Clin Infect Dis* 2005; **40** Suppl 6: S379–83.
- 65** Perfect JR. Treatment of non-*Aspergillus* moulds in immunocompromised patients, with amphotericin B lipid complex. *Clin Infect Dis* 2005; **40** Suppl 6: S401–8.
- 66** Yustes C, Guarro J. In vitro synergistic interaction between amphotericin B and micafungin against *Scedosporium* spp. *Antimicrob Agents Chemother* 2005; **49**: 3498–500.
- 67** Perrie RC, Ellis DH. In vitro synergy between terbinafine and voriconazole against *Scedosporium prolificans*. In: *Abstracts of Forty-second Interscience Conference on Antimicrobial Agents and Chemotherapy, San Diego, CA, 2002*. Abstract M-862, p. 42. American Society for Microbiology, Washington, DC, USA.
- 68** Cannon RD, Lamping E, Holmes AR *et al*. Efflux-mediated antifungal drug resistance. *Clin Microbiol Rev* 2009; **22**: 291–321.
- 69** Walsh TJ, Anaissie EJ, Denning DW *et al*. Treatment of aspergillosis: clinical practice guidelines of the Infectious Diseases Society of America. *Clin Infect Dis* 2008; **46**: 327–60.
- 70** Verweij PE, Mellado E, Melchers WJ. Multiple-triazole-resistant aspergillosis. *N Engl J Med* 2007; **356**: 1481–3.

- 71 Pascual A, Calandra T, Bolay S *et al.* Voriconazole therapeutic drug monitoring in patients with invasive mycoses improves efficacy and safety outcomes. *Clin Infect Dis* 2008; **46**: 201–11.
- 72 Smith J, Safdar N, Knasinski V *et al.* Voriconazole therapeutic drug monitoring. *Antimicrob Agents Chemother* 2006; **50**: 1570–2.
- 73 Andes D, Pascual A, Marchetti O. Antifungal therapeutic drug monitoring: established and emerging indications. *Antimicrob Agents Chemother* 2009; **53**: 24–34.
- 74 Krishna G, Martinho M, Chandrasekar P *et al.* Pharmacokinetics of oral posaconazole in allogeneic hematopoietic stem cell transplant recipients with graft-versus-host disease. *Pharmacotherapy* 2007; **27**: 1627–36.
- 75 Purkins L, Wood N, Ghahramani P *et al.* Pharmacokinetics and safety of voriconazole following intravenous- to oral-dose escalation regimens. *Antimicrob Agents Chemother* 2002; **46**: 2546–53.
- 76 Hakki M, Staab JF, Marr KA. Emergence of a *Candida krusei* isolate with reduced susceptibility to caspofungin during therapy. *Antimicrob Agents Chemother* 2006; **50**: 2522–4.
- 77 Hernandez S, López-Ribot JL, Najvar LK *et al.* Caspofungin resistance in *Candida albicans*: correlating clinical outcome with laboratory susceptibility testing of three isogenic isolates serially obtained from a patient with progressive *Candida* esophagitis. *Antimicrob Agents Chemother* 2004; **48**: 1382–3.
- 78 Laverdière M, Lalonde RG, Baril JG *et al.* Progressive loss of echinocandin activity following prolonged use for treatment of *Candida albicans* oesophagitis. *J Antimicrob Chemother* 2006; **57**: 705–8.
- 79 Moudgal V, Little T, Boikov D *et al.* Multiechinocandin- and multiazole-resistant *Candida parapsilosis* isolates serially obtained during therapy for prosthetic valve endocarditis. *Antimicrob Agents Chemother* 2005; **49**: 767–9.
- 80 Gubbins PO, Heldenbrand S. Clinically relevant drug interactions of current antifungal agents. *Mycoses* 2010; **53**: 95–113.
- 81 Saliba F, Dupont B. Renal impairment and amphotericin B formulations in patients with invasive fungal infections. *Med Mycology* 2008; **46**: 97–112.
- 82 Walsh TJ, Finberg RW, Arndt C *et al.* Liposomal amphotericin B for empirical therapy in patients with persistent fever and neutropenia. National Institute of Allergy and Infectious Diseases Mycoses Study Group. *N Engl J Med* 1999; **340**: 764–71.
- 83 Song JC, Deresinski S. Hepatotoxicity of antifungal agents. *Curr Opin Investig Drugs* 2005; **6**: 170–7.
- 84 Cannon JP, Garey KW, Danziger LH. A prospective and retrospective analysis of the nephrotoxicity and efficacy of lipid-based amphotericin B formulations. *Pharmacotherapy* 2001; **21**: 1107–14.
- 85 Fleming RV, Kantarjian HM, Husni R *et al.* Comparison of amphotericin B lipid complex (ABLC) vs. ambisome in the treatment of suspected or documented fungal infections in patients with leukemia. *Leuk Lymphoma* 2001; **40**: 511–20.
- 86 Malani PN, Depestel DD, Riddell J *et al.* Experience with community-based amphotericin B infusion therapy. *Pharmacotherapy* 2005; **25**: 690–7.
- 87 Mattiuzzi GN, Kantarjian H, Faderl S *et al.* Amphotericin B lipid complex as prophylaxis of invasive fungal infections in patients with acute myelogenous leukemia and myelodysplastic syndrome undergoing induction chemotherapy. *Cancer* 2004; **100**: 581–9.
- 88 Wingard JR, White MH, Anaissie E *et al.* A randomized, double-blind comparative trial evaluating the safety of liposomal amphotericin B versus amphotericin B lipid complex in the empirical treatment of febrile neutropenia. L Amph/ABLC Collaborative Study Group. *Clin Infect Dis* 2000; **31**: 1155–6.
- 89 Safdar A, Ma J, Saliba F *et al.* A review and meta-analysis of drug-induced nephrotoxicity caused by amphotericin B lipid complex and liposomal amphotericin B. *Medicine (Baltimore)* 2010; **89**: 236–44.
- 90 Marty FM, Cosimi LA, Baden LR. Breakthrough zygomycosis after voriconazole treatment in recipients of hematopoietic stem-cell transplants. *N Engl J Med* 2004; **350**: 950–2.
- 91 Madureira A, Bergeron A, Lacroix C *et al.* Breakthrough invasive aspergillosis in allogeneic haematopoietic stem cell transplant recipients treated with caspofungin. *Int J Antimicrob Agents* 2007; **30**: 551–4.
- 92 Trifilio S, Singhal S, Williams S *et al.* Breakthrough fungal infections after allogeneic hematopoietic stem cell transplantation in patients on prophylactic voriconazole. *Bone Marrow Transplant* 2007; **40**: 451–6.
- 93 Imhof A, Balajee SA, Fredricks DN *et al.* Breakthrough fungal infections in stem cell transplant recipients receiving voriconazole. *Clin Infect Dis* 2004; **39**: 743–6.